

## INDICATIONS:

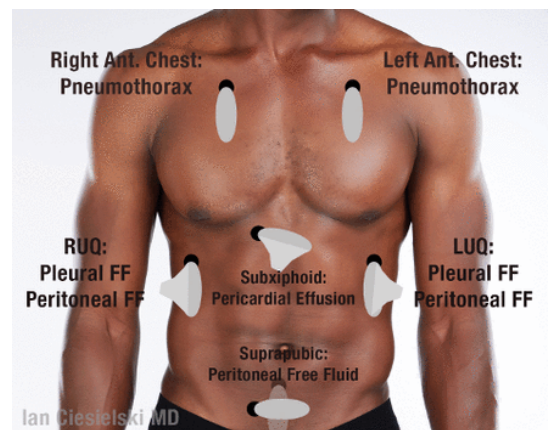
- As per Traumatic Cardiac Arrest [T-02], Chest/Abdominal Trauma [T-09], or other trauma guidelines

## CONTRAINDICATIONS:

- Any use impeding or delaying other critical interventions during an ongoing trauma resuscitation.

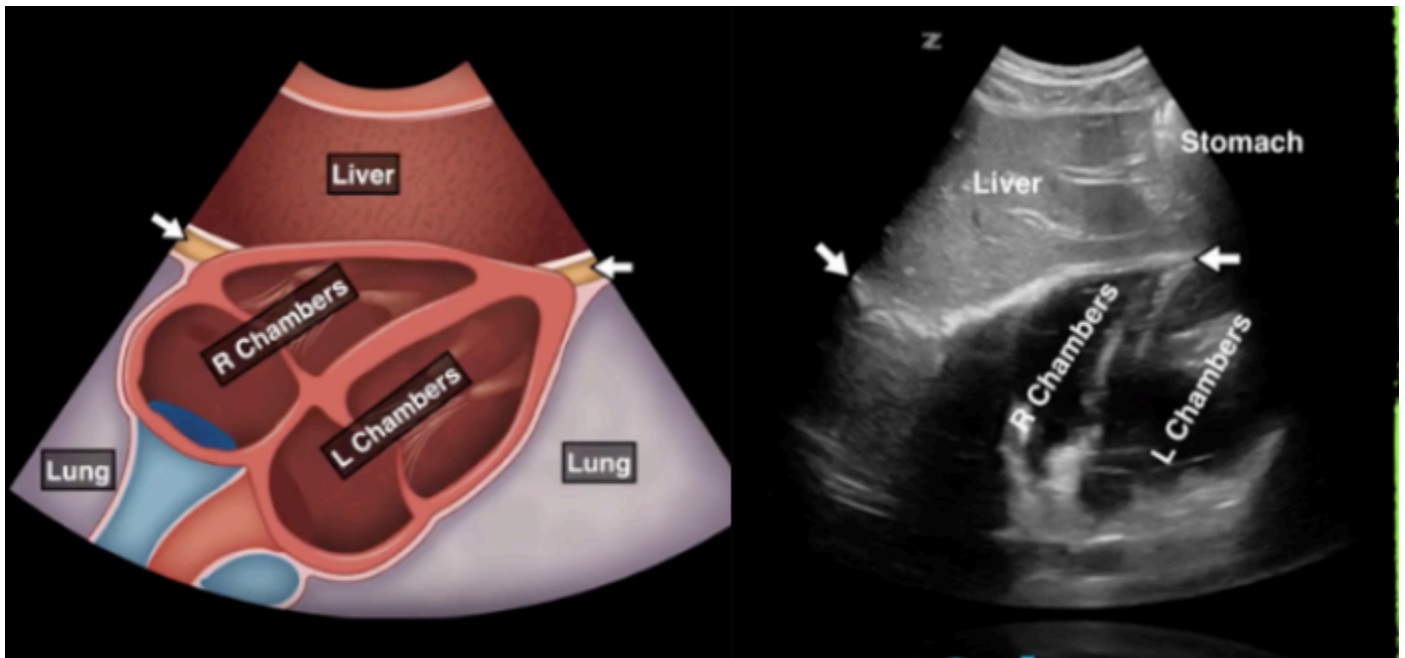
## Procedure (E-FAST ULTRASOUND EXAM):

- Assemble necessary equipment, including ultrasound cover and gel.
- Position the ultrasound probe in the appropriate anatomical locations.
- Obtain appropriate visualization of the six (6) recommended views, and determine the presence or absence of positive findings:
  - Subxiphoid (Cardiac)
  - Right Upper Quadrant (Liver)
  - Left Upper Quadrant (Spleen)
  - Suprapubic (Pelvis)
  - Right Anterior Chest (Right Lung)
  - Left Anterior Chest (Left Lung)
- Continue resuscitative efforts, as per referenced clinical guideline(s), utilizing the ultrasound findings to determine appropriate prehospital interventions, destination/method of transport, and prenotification of the appropriate trauma center.
- Save images to the device and upload them to the PCR, as per agency policy.
- Document utilization, timing, findings/interpretation, and any clinical decision making based on the ultrasound in the PCR.



Note: Other views may be utilized if the subxiphoid view is unsatisfactory, as long as they do not interfere with other necessary interventions.

#1 Subxiphoid (Cardiac) View:

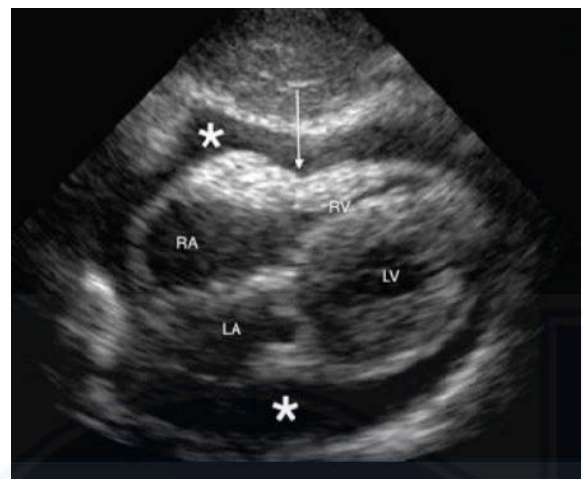


Positive Findings:

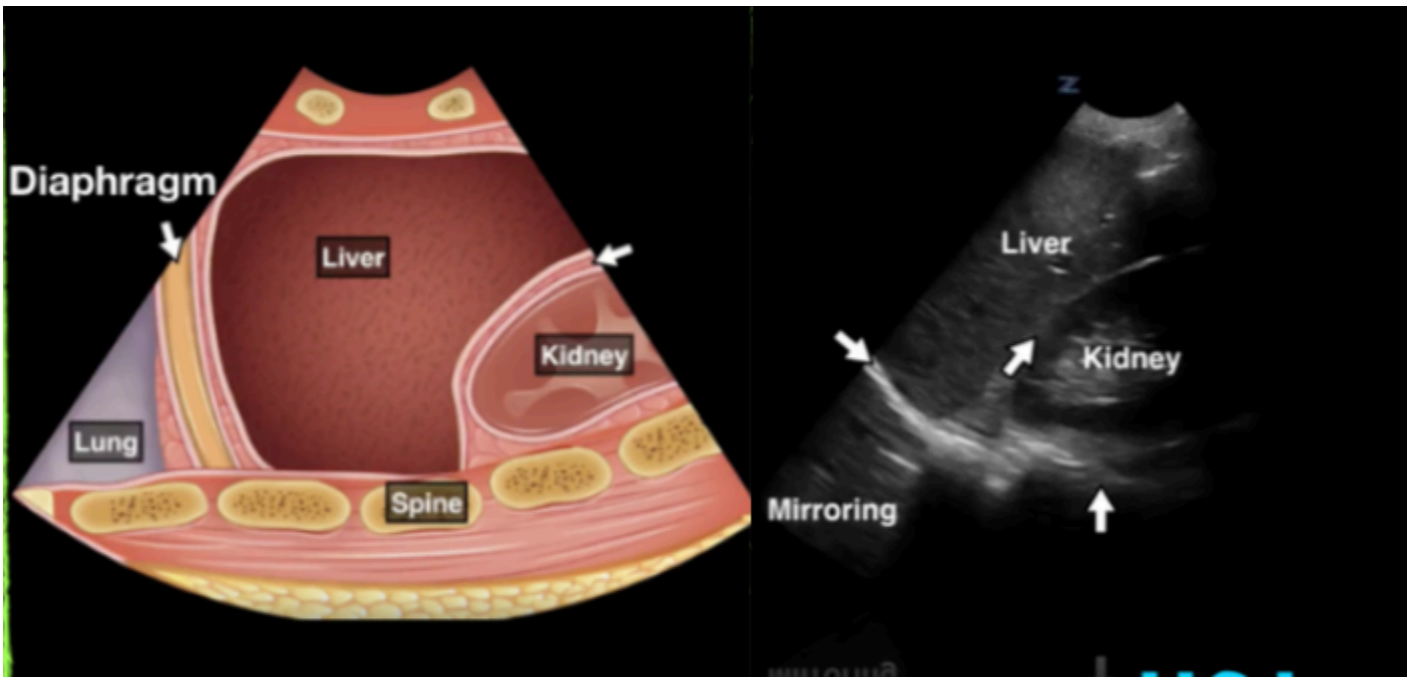
- **Pericardial Effusion** (fluid/blood around the heart), as demonstrated on the image to the right.

Other Notable Findings:

- Cardiac motion (i.e. squeeze)

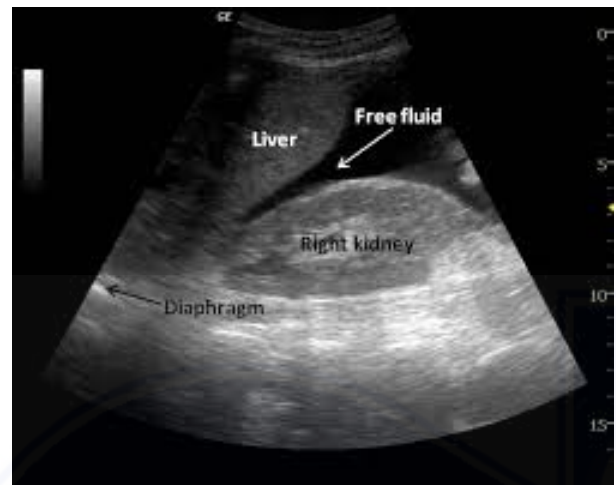

#2 Right Upper Quadrant (Liver) View:

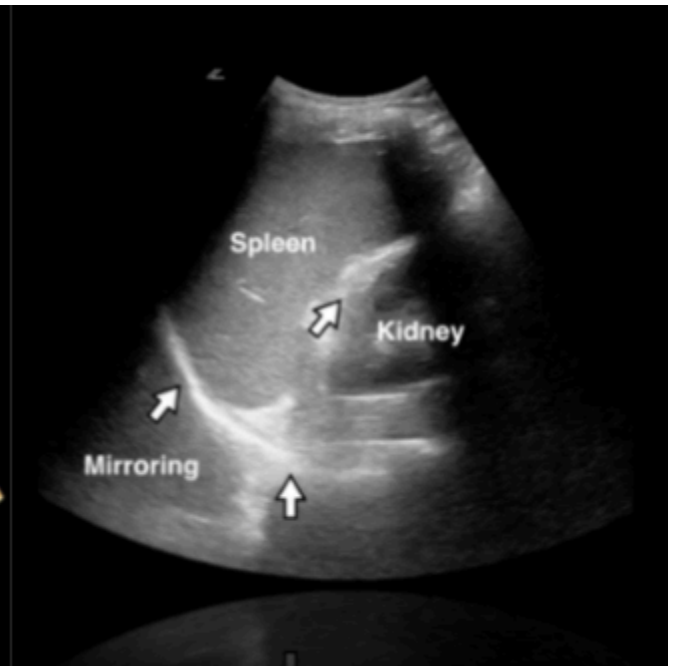
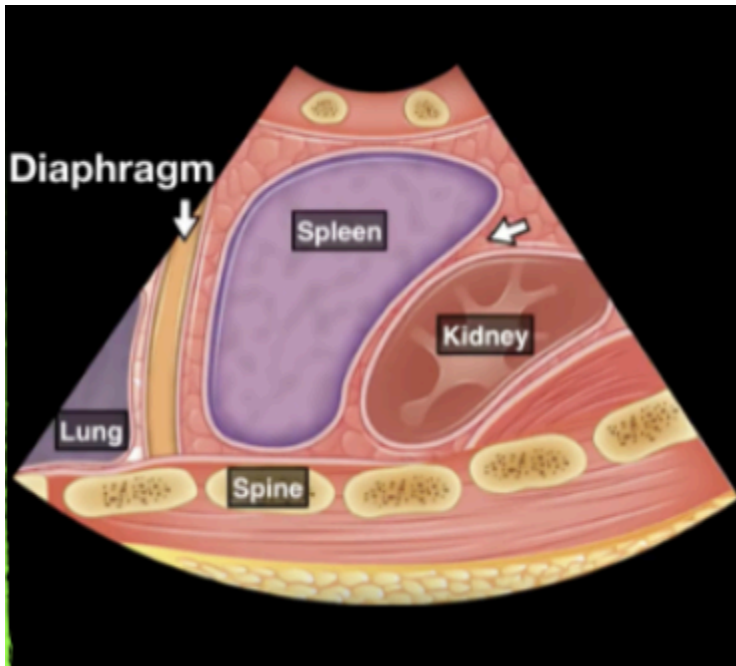


Positive Findings:

- **Peritoneal Fluid** (fluid/blood between the liver and kidney, i.e. Morrison's Pouch), as demonstrated on the image to the right.

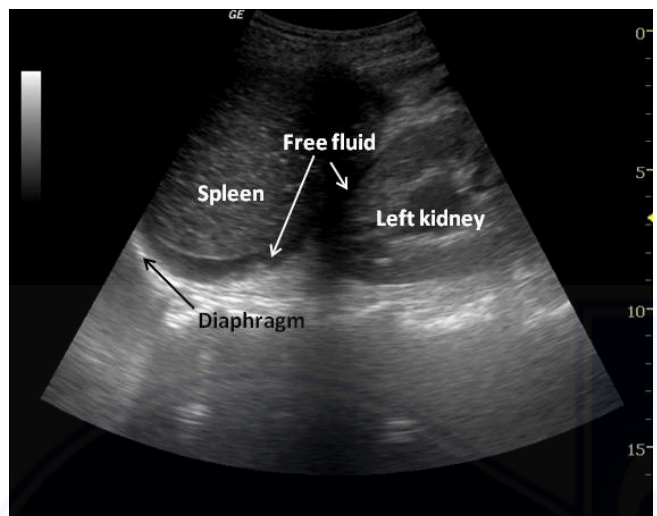


#3 Left Upper Quadrant (Spleen) View:

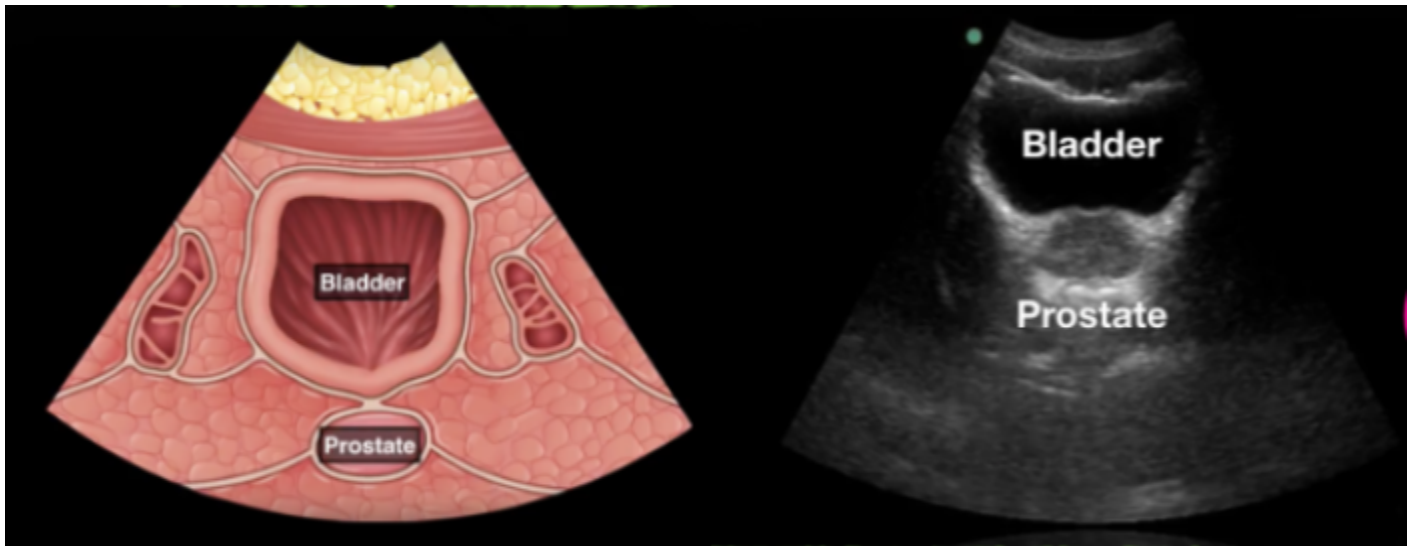


Positive Findings:

- **Peritoneal Fluid** (fluid/blood between the spleen and kidney), as demonstrated on the image to the right.

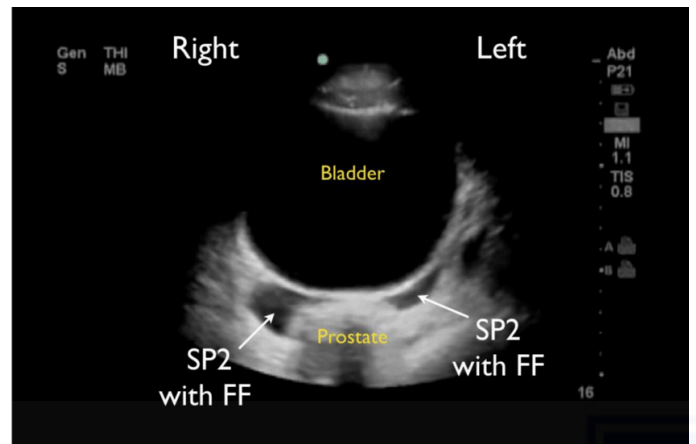


#4 Suprapubic (Pelvis) View:

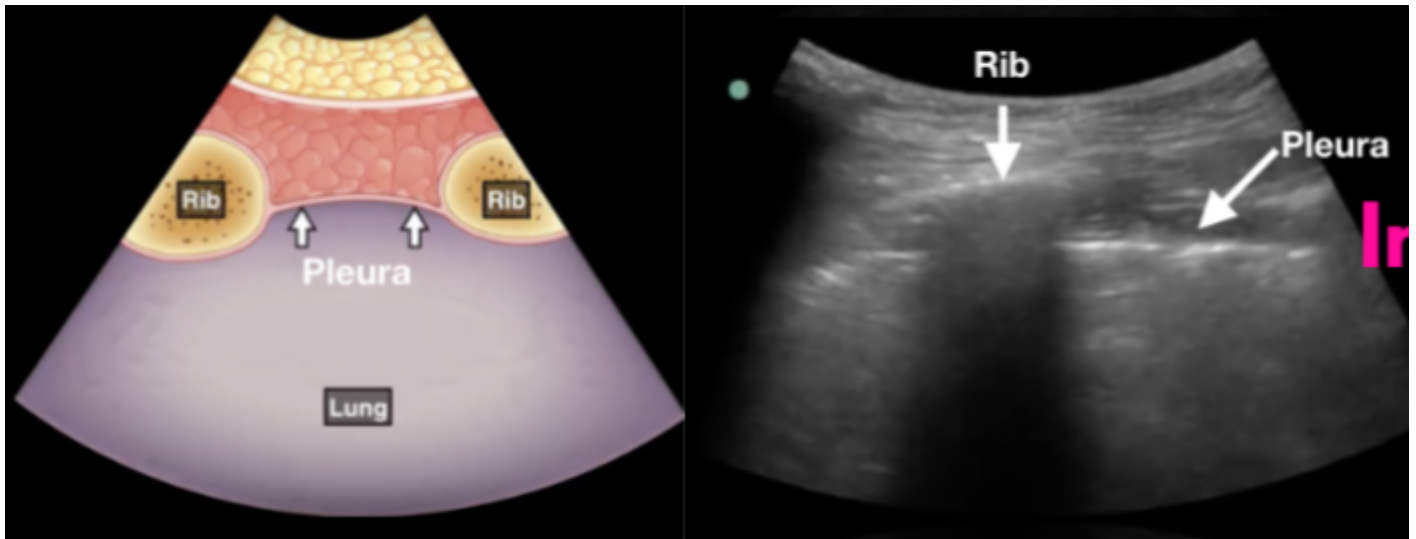


Positive Findings:

- **Peritoneal/Pelvic Free Fluid** (fluid/blood in the pelvis, generally behind the bladder), as demonstrated on the image to the right.

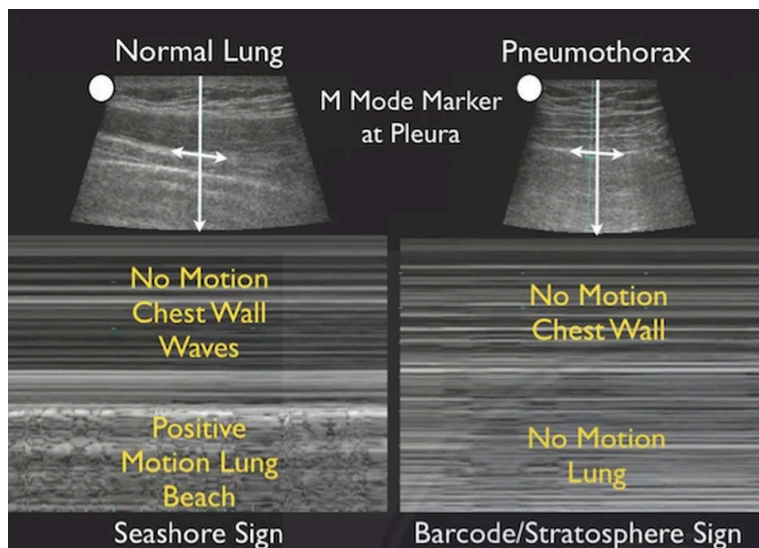


#5 Right and #6 Left Chest



Positive Findings:

- **Pneumothorax**, as demonstrated on the image below with a lack of visualized lung sliding. 'M Mode' can also be used to determine the presence or absence of lung sliding.



1-P6  
ULTRASOUND:  
E-FAST

Ultrasound use requires service/  
device-level training and credentialing  
by the EMS Medical Director.

First Responder  
EMT  
AEMT  
Paramedic

### QI Review Parameters:

1. {Pending}